

A Rare Case of Asymptomatic External Ophthalmomyiasis Manifesting with Corneal Ulcer

Saeed Shokoohi Rad¹ (MD), Seyedeh Fatemeh Irandoust^{1*} (MD); Sadeq Ghafarian¹ (MD)

¹: Cornea Research Centre, Eye Research Centre, Khatam-al-Anbia Hospital, Faculty of Medicine, Mashhad University of Medical Sciences, Mashhad, Iran.

ARTICLE INFO

Article type:

Case Report

Article history:

Received: 13-Oct-2015

Accepted: 3-Nov-2015

Keywords:

Corneal infiltration
Corneal ulcer
Oestrus ovis
Ophthalmomyiasis

ABSTRACT

Introduction: To report a rare case of asymptomatic external ophthalmomyiasis manifesting with chronic corneal ulcer.

Case: A 65-year-old diabetic female, residing in a rural area, was admitted to Khatam-al-Anbia Eye Hospital for diabetic retinopathy evaluation. The patient had no ocular surface complaints. On examination, her best-corrected visual acuity was counting fingers in the right eye and 4/20 in the left eye. A chronic corneal ulcer (similar to ocular herpes) was accidentally diagnosed in the superior cornea with three dead larvae in the superior tarsal conjunctiva. High-power magnified biomicroscopic examination did not indicate any intraocular infestation. Fundus examination revealed severe non-proliferative diabetic retinopathy and clinically significant macular edema in both eyes. After removing the dead larvae, the ulcer improved within one week by topical antibiotics and frequent use of lubricant. The patient did not experience any relapse during the three-month follow-up.

Conclusion: Ophthalmomyiasis can be a differential diagnosis for corneal ulcers. Therefore, this rare asymptomatic case must be considered in immunocompromised patients, particularly in rural areas.

► Please cite this paper as:

Shokoohi Rad S, Irandoust S.F, Ghafarian S. A Rare Case of Asymptomatic External Ophthalmomyiasis Manifesting with a Corneal Ulcer. Patient Saf Qual Improv. 2016; 4(1): 344-345.

Introduction

Myiasis occurs when maggots invade and feed on the living or dead tissues of humans or animals. *Oestrus ovis* (sheep botfly) is regarded as the most common cause of ophthalmomyiasis in rural areas (1). Ophthalmomyiasis results from the external or internal infestation of the eye. External ophthalmomyiasis involves superficial ocular structures, and its symptoms at presentation may mimic allergy or viral conjunctivitis (2).

Untreated external ophthalmomyiasis may lead to the internal form of the disease in which the larvae penetrate the sclera and invade sub-retinal and retinal tissues, causing severe tissue damages (3).

Case report

A 65-year-old diabetic female, residing in a rural area, was admitted to Khatam-al-Anbia Eye Hospital for diabetic retinopathy evaluation. The patient had no ocular surface complaints. On examination, her best-corrected visual acuity was counting fingers in the right eye and 4/20 in the left eye.

Slit-lamp examination of the left eye indicated two

corneal ulcers (similar to ocular herpes) including epithelial defect, stromal thinning, stromal infiltration, and vascularization in the upper half of the cornea (Figure 1).

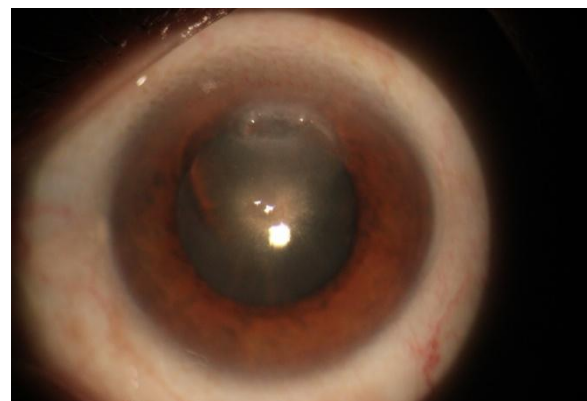


Figure1: Two corneal ulcers of the left eye (epithelial defect, infiltration, and thinning).

In the superior tarsal conjunctiva, we discovered three partially subconjunctival larvae (Figure 2). High-

power magnified biomicroscopic examination did not reveal any intraocular infestation. Fundus examination showed severe non-proliferative diabetic retinopathy and Clinically Significant Macular Edema (CSME) in both eyes.

The three dead larvae were removed with forceps and the patient was treated with topical antibiotics and frequent use of lubricant. Following the treatment, the corneal ulcer was completely resolved within one week. The patient did not experience any relapse during the three-month follow-up.

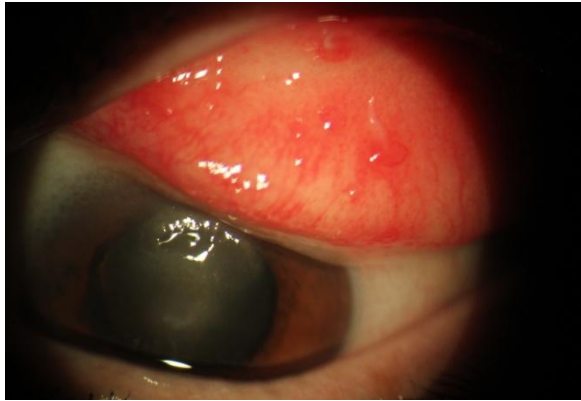


Figure2: Partially subconjunctival larvae, associated with corneal ulcers.

Discussion

External ophthalmomyiasis is the most common form of ophthalmomyiasis, only involving the external surface of the eye. Considering the fact that the symptoms of external ophthalmomyiasis are non-specific, this condition might be misdiagnosed with other types of conjunctivitis (4).

In the literature, keratouveitis has been reported after conjunctivitis (3). Laborde et al. reported a case of intracorneal ophthalmomyiasis deep in the stroma, with several linear stromal tracks and no inflammatory signs (5). Moreover, Perry et al. described a patient with a white linear scar, extending from the corneal surface to midstroma and stromal keratitis caused by larvae (6).

Also, in three cases, peripheral corneal infiltration

References

- 1- Grammer J, Erb C, Kamin G, Wild M, Riedinger C, Kosmidis P, et al. Ophthalmomyiasis externa due to the sheep botfly *Oestrus ovis* (Diptera: Oestridae) in southwest Germany. *German journal of ophthalmology*. 1995 May;4(3):188-95.
- 2- Gupta VP, Baveja UK. Ophthalmomyiasis externa caused by the sheep nasal botfly *Oestrus ovis*. *Indian journal of ophthalmology*. 1988 Jan-Mar;36(1):41-2.
- 3- Jenzeri S, Ammari W, Attia S, Zaouali S, Babba H, Messaoud R, et al. External ophthalmomyiasis manifesting with keratouveitis. *International ophthalmology*. 2009 Dec;29(6):533-5.
- 4- Akdemir MO, Ozen S. External ophthalmomyiasis caused by *Oestrus ovis* misdiagnosed as bacterial conjunctivitis. *Tropical doctor*. 2013 Jul;43(3):120-3.
- 5- Laborde RP, Kaufman HE, Beyer WB. Intracorneal ophthalmomyiasis. Case report. *Archives of ophthalmology (Chicago, Ill: 1960)*. 1988 Jul;106(7):880-1.
- 6- Perry HD, Donnenfeld ED, Font RL. Intracorneal ophthalmomyiasis. *American journal of ophthalmology*. 1990 Jun 15;109(6):741-2.
- 7- Gholamhossein Y, Behrouz H. External ophthalmomyiasis presenting to an emergency department: corneal findings as a sign of *Oestrus ovis*. *Korean journal of ophthalmology: KJO*. 2013 Oct;27(5):341-4.

has been reported as a sign of ophthalmomyiasis (7).

Predisposing factors for ophthalmomyiasis include eye infections, ocular wounds, aging, and immunocompromised conditions. External ophthalmomyiasis usually has an acute presentation and patients have ocular surface complaints such as tearing, itching, foreign body sensation, hyperemia, lid swelling, and chemosis.

In the present case, the patient was a diabetic female with no prior history of ocular myiasis or conjunctivitis symptoms. She had no ocular surface complaints and was accidentally diagnosed with a corneal ulcer and subconjunctival larvae; therefore, the indolent and chronic form of external ophthalmomyiasis was confirmed in the patient.

This is the first report on asymptomatic external ophthalmomyiasis in the literature, in which the conjunctiva involved with secondary corneal involvement. It is not clear whether the etiology of corneal ulcer is mechanical trauma or immunologic insult. We speculate that dead subconjunctival larvae may play a role similar to foreign body and induce mechanical trauma in the corneal surface. Our patient had poorly controlled diabetes, which was a predisposing factor for ocular infestation.

Extensive larval infestation of a compromised external eye results in the total destruction of orbital contents. Therefore, timely diagnosis and treatment of these patients are important for preventing the complications.

Conclusion

Although external ophthalmomyiasis usually manifests with ocular surface problems, this rare asymptomatic case must be considered in patients suffering from the chronic form of the disease, especially in rural areas. Posterior eyelid examination can be helpful in patients with corneal ulcer in endemic regions.

Acknowledgements

We would like to thank Mr. Khosravi for his assistance in taking images of the patient.