

## Clinical and Electrophysiological Report of a Unilateral Retinitis Pigmentosa Case

Mohammad Reza Sedaghat<sup>1</sup> (MD); Seyed-Amir Askari<sup>2\*</sup> (MD); Rowshanak Afshar<sup>3</sup> (MD)

<sup>1</sup> Patient Safety Research Center, Imam Reza Hospital, Faculty of Medicine, Mashhad University of Medical Sciences, Mashhad, Iran.

<sup>2</sup> Cornea Research Centre, Khatam-al-Anbia Hospital, Faculty of Medicine, Mashhad University of Medical Sciences, Mashhad, Iran.

<sup>3</sup> Department of Medicine Gordon and Leslie Diamond Centre, Vancouver, University of British Columbia, Canada.

### ARTICLE INFO

#### Article type:

Case Report

#### Article history:

Received: 19- Dec-2013

Accepted: 6- Jan-2014

#### Keywords:

Electro-oculography

Electro-retinography

Unilateral retinitis pigmentosa

### ABSTRACT

**Introduction:** To describe clinical and electrophysiological features of a patient with unilateral Retinitis Pigmentosa (RP).

**Case:** A 29-year-old female with history of progressive visual disturbance in the right eye has undergone multiple eye examinations during the past eight years. There was nothing noticeable in her past medical and ocular history. Comprehensive eye examinations were done in the first visit. All data was suggestive of right eye RP. Posterior segment fundal examination findings were: a pallor waxy disc, vessel attenuation, and extended pigmentary degeneration of the mid-peripheral retina. The left eye examination was normal. Comparing the automated 60 degree and 30 degree visual fields of both eyes obviously showed significant defects in the right eye visual field but normal in the left eye. All of the probable infectious agents, which can cause similar ocular manifestations, were ruled out by serological tests. The standard photopic and scotopic electroretinographies were significantly reduced in amplitude in the right eye. Also, the standard Electro-Oculography (EOG) results were the same as the Electro-Retinography (ERG) ones in both eyes. Eye examinations were normal in other family members. Over an eight-year follow-up period, progressive deteriorating vision has gradually become more noticeable in the right eye. The left eye has been completely normal since. This data was compatible with the Francois and Verriesr unilateral RP diagnostic criteria.

**Conclusion:** Clinical signs and symptoms, a minimum of a five-year follow-up period, and confirmatory ERG and EOG are very helpful to diagnose and affirm the case of unilateral RP.

#### ► Please cite this paper as:

Sedaghat MR, Askari S.A, Afshar R. Clinical and Electrophysiological Report of a Unilateral Retinitis Pigmentosa Case. Patient Saf Qual Improv. 2014; 2(2):106-109.

### Introduction

Retinitis Pigmentosa (RP) is a group of inherited disorders which are known by progressive dysfunction, cell loss, and finally atrophy of retinal tissue.

Initial disturbance of photoreceptors causes subsequent damage to inner retinal cells. After a while, there is a widespread atrophy of several layers of retina (In some cases most layers are involved.). Night blindness and visual field loss are the initial consequents of RP. The final consequent of RP manifests itself as central visual dysfunction (1).

Narrowed retinal vessels, mottling and granularity of the retinal pigment epithelium and migration of pigments from the disrupted retinal pigment epithelium in to the retina to form clumps of various sizes or bone

Spicule formation is the significant changes which are occurred in the fundus.

Also, atrophy of the retinal pigment epithelium and choriocapillaris are the final changes made in the fundus (2, 3). Unilateral retinal degeneration is a misnomer which can be described more properly by the term unilateral retinitis pigmentosa. Although functional and ophthalmoscopic changes are obvious in the affected eye, there is no symptom and ERG (Electroretinogram) abnormalities in the fellow eye during years (4). To diagnose the primitive URP, the Francois and Verriesr criteria are needed:

1. Exclusion of all infective etiologies.
2. Checking the clinical signs of retinitis presented in

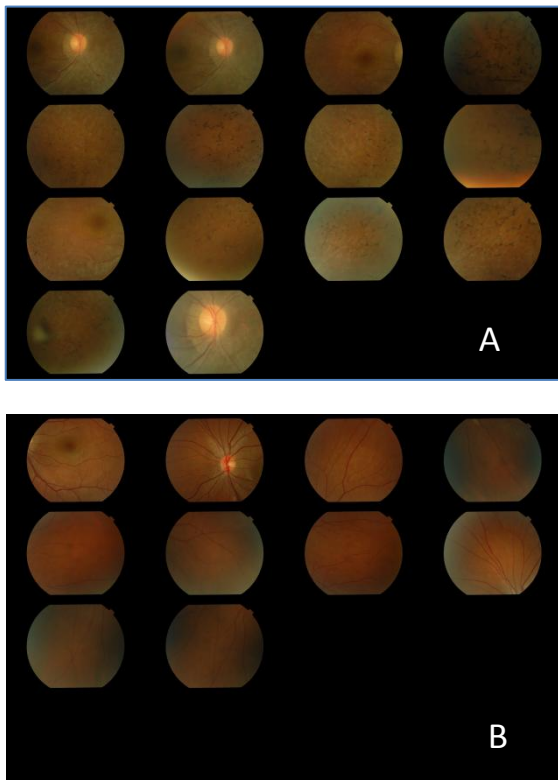
the affected eye.

3. Making sure there is no symptom in the fellow eye.
4. Using a long follow-up period (at least five years)(2).

Determining if ERG and EOG (Electro-oculogram) will be the two reliable and useful examinations to diagnose the disorder, if they are performed according to ISCEV (International Society for Clinical Electrophysiology Vision) standards (5, 6).

**Case**

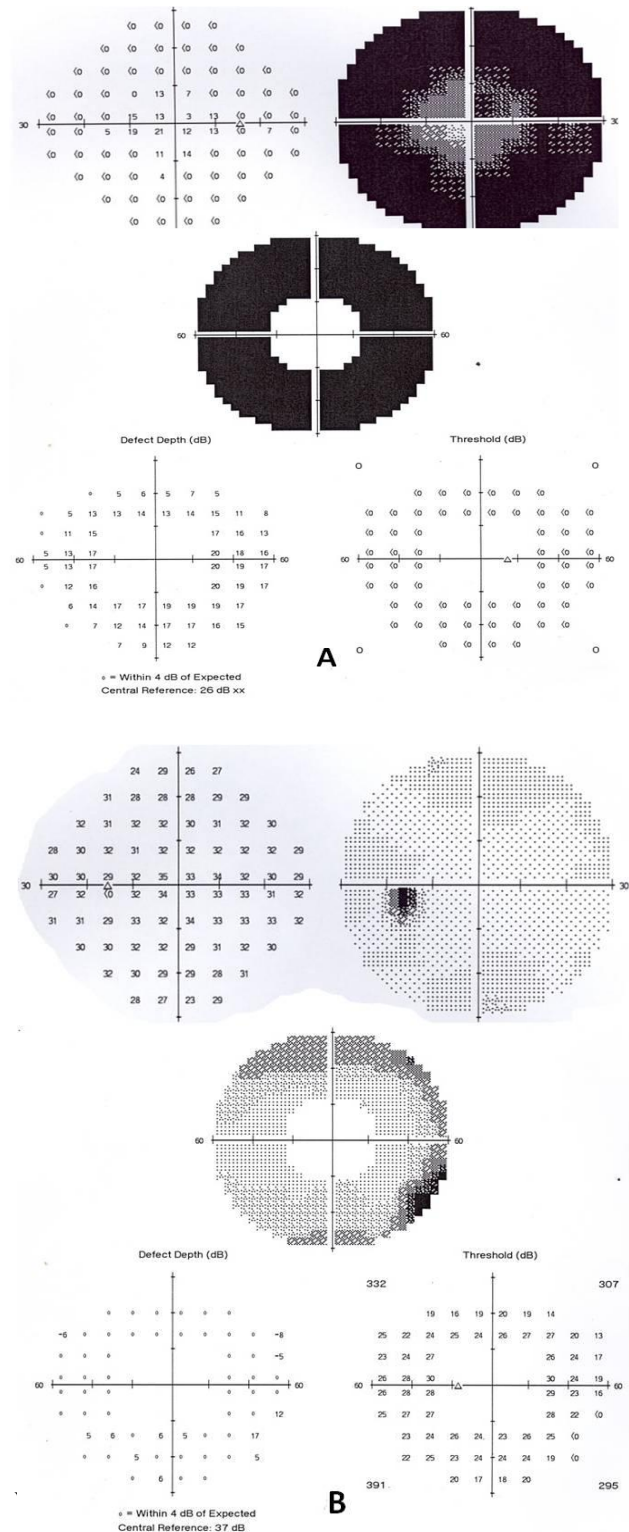
A 29-year-old female with a long history of visual disturbance in the right eye underwent an eye examination eight years ago. Her chief complaint was night blindness without photophobia and colour vision problem. She did not have any history of ocular trauma or surgery. At the time of the first visit, the Best Corrected Visual Acuity (BCVA) in the Right Eye (RE) was 20/22 and in the Left Eye (LE) was 20/20. The biomicroscopic anterior segment examination was normal in both eyes. Although bone spicule degeneration appearance in the midperiphery area, waxy disc palor and vessel attenuation were obvious in the fundus examination of RE, The fundus examination of LE was completely normal (Figure1).



**Figure1: Fundus photograph of the RE (A) and fundus photograph of the LE (B).**

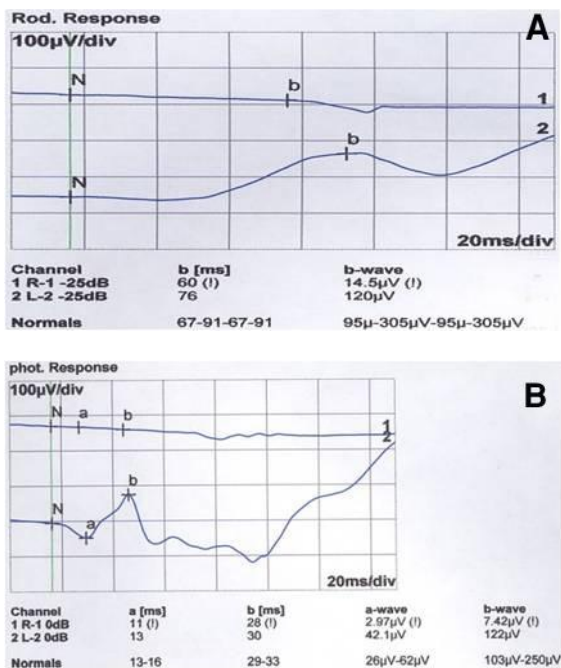
The patient was diagnosed as a suspected unilateral RP case. Serological surveys to rule out all the infectious agents – which might cause the similar retinal appearance – were negative. There was no affected person in the patient’s family. Also, the patient’s mother did not have any history of infection

during pregnancy. Wide-field computerized perimetry, ERG and EOG were performed. Despite the generalized sensitivity reduction and restricted visual field with central island in the RE computerized field examination, the LE was totally normal (Figure2).



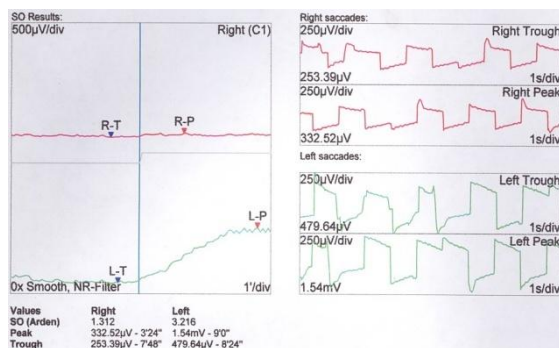
**Figure2: The visual field of the RE (A) and the visual field of the LE (B).**

While the standard photopic and scotopic ERGs were normal in the LE, they were markedly reduced in the RE (Figure3).



**Figure 3: The scotopic ERGs of both eyes (A) and the photopic ERGs of both ones.**

The result of the standard EOG was normal in the LE and subnormal in the RE (Figure4).



**Figure 4: The EOG of both eyes. Clinical and electrophysiological report of URP.**

With respect to probable diagnosis as a suspected unilateral RP case and the lack of treatment, she was just followed up. After an eight-year follow-up, the BCVA of RE decreased to 20/28; however, the BCVA of LE remained 20/20. Although the pigmentary degeneration of midperipheral retina was worsened in

## References

- 1- Weleber R, Gregory-Evans K. Retinitis pigmentosa and allied disorders. *Retina*. 2001;1:362-460.
- 2- Spadea L, Magni R, Rinaldi G, Dragani T, Bianco G. Unilateral retinitis pigmentosa: clinical and electrophysiological report of four cases.

the RE, no changes were seen in the LE. Serial field examination could not find any abnormality in patient's left eye.

However, a progressive visual field defect has been the main characteristic of these assessments in the right eye.

## Discussion

While RP appears to be an inherited disorder- either as an autosomal or X-linked trait- URP is more frequently sporadic and in adult ages (7,8).

The etiologies are usually not known, but there are some documented causes which can lead to this disorder such as transient ophthalmic artery occlusion, perforating injury to the eye without direct trauma to the retina (9), and structural defects like pit of the optic disc with prolonged serous retinal detachment (4).

Despite the large number of bilateral RP cases, the URP cases are much more infrequent and rare because of its progression in two eyes during years (10). The rarity of URP has clarified the importance of electrofunctional examinations (5, 6). To diagnose better in this case, a long follow-up period is needed in order to find the clinical signs in the affected eye and no related changes of RP in the fellow eye (2).

The case presented in this article conforms to the four proposed criteria to justify the presumptive URP (11): Long disease duration (over five years), presence of functional changes and an ophthalmoscopic appearance of typical primary pigmentary degeneration in affected eye, no clinical and electrophysiological change in unaffected eye, and exclusion of an inflammatory cause. In some studies, it is shown that the ERG abnormalities are seen even without any ophthalmoscopic fundus involvement (12).

In addition to making the diagnosis, the severity of ERG abnormalities is proportional to the extent of the involved area which is beneficial to monitor either the progression of the disorder or absence of the disorder (13). EOG is also useful to confirm the unilaterality of RP, as ERG is helpful to exclude the involvement of the fellow eye or the possibility of different progression of bilateral RP (2). Unfortunately, there is not any treatment for RP at present, but definite diagnosis is crucial because other diseases in the differential diagnosis of RP have effective proved treatment.

To conclude, characteristic clinical signs and symptoms with ipsilateral abnormal ERG and EOG with long term follow-up are very helpful to diagnose and confirm the case of unilateral RP.

- Ophthalmologica Journal international  
d'ophtalmologie International journal of  
ophthalmology Zeitschrift fur Augenheilkunde.  
1998;212(5):350-4.  
3- Thakur A, Puri L. Unilateral retinitis pigmentosa.

- Clinical & experimental optometry : journal of the Australian Optometrical Association. 2010 Mar;93(2):102-4.
- 4- Pagon RA. Retinitis pigmentosa. Survey of ophthalmology. 1988 Nov-Dec;33(3):137-77.
  - 5- Marmor MF, Zrenner E. Standard for clinical electroretinography (1994 update). Documenta ophthalmologica Advances in ophthalmology. 1995;89(3):199-210.
  - 6- Marmor MF, Zrenner E. Standard for clinical electro-oculography. International Society for Clinical Electrophysiology of Vision. Documenta ophthalmologica Advances in ophthalmology. 1993;85(2):115-24.
  - 7- Boughman JA, Fishman GA. A genetic analysis of retinitis pigmentosa. The British journal of ophthalmology. 1983 Jul;67(7):449-54.
  - 8- Bunker CH, Berson EL, Bromley WC, Hayes RP, Roderick TH. Prevalence of retinitis pigmentosa in Maine. American journal of ophthalmology. 1984 Mar;97(3):357-65.
  - 9- Bastek JV, Foos RY, Heckenlively J. Traumatic pigmentary retinopathy. American journal of ophthalmology. 1981 Nov;92(5):621-4.
  - 10- Paolo de Felice G, Bottoni F, Orzalesi N. Unilateral retinitis pigmentosa associated with exfoliation syndrome. International ophthalmology. 1988 Feb;11(4):219-26.
  - 11- Chen H, Wu D, Huang S, Jiang F. Unilateral retinitis pigmentosa with amblyopia in the fellow eye. Graefe's archive for clinical and experimental ophthalmology = Albrecht von Graefes Archiv fur klinische und experimentelle Ophthalmologie. 2006 Dec;244(12):1701-4.12-
  - 12- Berson E. Retinitis pigmentosa: Some observations on the course. Principles and practice of clinical electrophysiology of vision St Louis: Mosby. 1991:501-9.
  - 13- Berson EL, Sandberg MA, Rosner B, Birch DG, Hanson AH. Natural course of retinitis pigmentosa over a three-year interval. American journal of ophthalmology. 1985 Mar 15;99(3):240-51.