

Nicotinic Acid Treatment for Retinal Vein Occlusion

Majid Abrishami¹ (MD); Mirnaghi Mousavi¹ (MD); Siamak Zarei-Ghanavati² (MD, FICO); Touka Banaee³ (MD); Mehran Zarei-Ghanavati^{4*} (MD)

¹ Professor of Ophthalmology, Khatam-Al-Anbia Eye Hospital, Mashhad University of Medical Science, Mashhad, Iran.

² Assistant Professor of Ophthalmology, Research Center for Patient Safety, Mashhad University of Medical Science, Mashhad, Iran.

³ Associate Professor of Ophthalmology, Khatam-Al-Anbia Eye Hospital, Mashhad University of Medical Science, Mashhad, Iran.

⁴ Assistant Professor of Ophthalmology, Farabi Eye Hospital, Tehran University of Medical Sciences, Tehran, Iran.

ARTICLE INFO	ABSTRACT
<p>Article type: Original Article</p> <hr/> <p>Article history: Received: 19-Oct-2013 Accepted: 5-Dec-2013</p> <hr/> <p>Keywords: BRVO CRVO Niacin Nicotinic acid Retinal Vein Occlusion</p>	<p>Introduction: To evaluate the effect of nicotinic acid in management of retinal vein occlusions (CRVO or BRVO).</p> <p>Materials and Methods: This prospective nonrandomized pilot study included 20 patients (21 eyes) with CRVO or BRVO that received nicotinic acid (3 g/day) for 3 months. A complete ophthalmologic examination uncorrected visual acuity (UCVA), best spectacle-corrected visual acuity (BSCVA), testing for a relative afferent pupillary defect (RAPD), slit-lamp examination, gonioscopy, intraocular pressure (IOP) measurement, funduscopy and fundus photography was performed.</p> <p>Results: Four patients did not appear for follow-up and hypersensitivity reaction to nicotinic acid and severe hyperglycemia happened in two patients. Therefore, the results of treatment in 16 eyes of 15 are reported. These patients had a mean age of 59.56 ± 11.12 years. The average length of follow-up was 8.6 ± 2.7 months. The mean BSCVA was 1.56 ± 0.66 before treatment, 1.38 ± 0.72 ($p > 0.05$) at one month and 0.88 ± 0.69 ($p < 0.01$) at three months. The last BSCVA of all 16 eyes averaged 0.97 ± 0.73 ($p < 0.01$). All patients had reduction of hemorrhagic events, cotton wool spots, edema in macula and disc, venous tortuosity, and dilation on basis of fundus photographs 3 months after treatment.</p> <p>Conclusion: Nicotinic acid usage provides enough time for development of collateral vessels, by induction of vasodilatation. Nicotinic acid use is tolerable and is related with mild systemic side effects.</p>

► Please cite this paper as:

Abrishami M, Zarei-Ghanavati S, Mousavi MN, Banaee T, Zarei-Ghanavati M. Nicotinic Acid Treatment for Retinal Vein Occlusion. Patient Saf Qual Improv. 2014; 2(1): 36-43.

Introduction

Retinal vein occlusion (RVO) is the second most common form of retinal vascular disorder after diabetic retinopathy. Central retinal vein occlusions (CRVO) involve the closure of the outflow of the retinal vein, which is most commonly due to thrombus formation. The current treatments for CRVO and branch retinal vein occlusion (BRVO) are based on the findings from the Central Vein Occlusion Study (CVOS) (1-2) and the Branch Vein Occlusion Study (BVOS) (3-4), respectively. Their treatment strategies are principally aimed at the treatment of subsequent complications of RVO.

Recently, several treatment options have been reported that attempt to restore retinal vein patency. These include the administration of recombinant tissue plasminogen activator (t-PA) (5), the creation of a chorioretinal anastomosis (6-7), radial optic neurotomy (RON), which attempts to relax the constriction of the central retinal vein (8-9), and arteriovenous sheathotomy that releases the pressure on the affected retinal vein branch (10). Nicotinic acid, which is also known as niacin, has been used for many years to treat hyperlipidemia (11).

© 2014 mums.ac.ir All rights reserved.

Corresponding Author: Mehran Zarei Ghanavati, Farabi Eye Hospital, Tehran University of Medical Sciences, Tehran, Iran.
Email: Mehran.Zarei@Yahoo.Com

The role of nicotinic acid as a vasodilator has recently been elucidated (12-13).

Vasodilation may help to restore some venous outflow in RVO. Nicotinic acid seems to be a good choice not only in this regard, but also because it has an anti-hyperlipidemic effect, which is additionally desirable for many of these patients and produces few side effects.

Materials and Methods

Between May 2006 and July 2007, 21 patients with CRVO or BRVO were enrolled in this study.

Written informed consent was obtained from all subjects before their entry into the study. Exclusion criteria included eyes with evidence of retinal neovascularization, vitreous hemorrhage, neovascular glaucoma, a history of previous laser photocoagulation. Patients with gout or active peptic ulcer disease were also excluded due to drug contraindication in these patients.

Follow-up examinations were performed weekly until the end of the first month, and were then carried out monthly. Additional examinations were performed on patient demand or if a complication occurred. Results from the following tests were obtained at the baseline and at monthly follow-up visits: the best spectacle-corrected visual acuity (BSCVA), the swinging flashlight test to detect the presence of a relative afferent pupillary defect (RAPD; ranked by a qualitative scale measurement rated between +1 to +4, where +1=barely detectable and +4=no direct pupillary response), slit-lamp examination, gonioscopy, measurement of intraocular pressure (IOP) using Goldmann applanation tonometry, indirect funduscopy, funduscopy with a slit lamp by non-contact lenses (90D), and fundus photography. Patients with a visual acuity (VA) of $\geq 20/200$ with 0 to +1 RAPD were considered to have non-ischemic CRVO, while those with a visual acuity that was less than 20/200 with a RAPD $\geq +2$ were considered to have ischemic CRVO. Blood pressure evaluations and laboratory investigations including fasting blood sugar (FBS), triglyceride, low density lipoprotein (LDL), and high density lipoprotein (HDL) measurements were carried out prior to treatment and at each follow-up visit. Humphrey automated perimetry was also performed at the baseline assessment and every three months thereafter. Laser treatment was performed if neovascular complications occurred during the study.

Drug and dosage

Incremental doses of oral nicotinic acid were given to all patients starting with one tablet (100 mg) every eight hours (300 mg daily), before the dose was increased by 300 mg/day (one tablet every eight hours) each week until a total dose of 3000 mg/day was reached in the tenth week of the study (ten tablets every eight hours). This dose was continued for two weeks before the drug was discontinued abruptly at the end of 12th week. To improve the compliance of patients in spite of the common side effect of skin flushing, aspirin (100 mg/day) was prescribed for the first month of the study and was taken in the morning.

Statistical Analysis

The Student *t* test was used for statistical analyses and performed using SPSS software (SPSS, Inc). The results are expressed as mean \pm SD. A *p* value less than 0.05 was considered statistically significant.

Results

Twenty one patients (12 males and 9 females) who were affected by RVO in at least one eye were treated with nicotinic acid. Informed consent was obtained in all patients. The average age of patients was 58.5 ± 12.0 years (range: 29 to 82 years). Five patients were hypertensive and one was diabetic.

One patient (Patient # 1) had antiphospholipid antibody syndrome and presented with bilateral multiple BRVOs six months after the onset of their systemic symptoms (Figure 1).

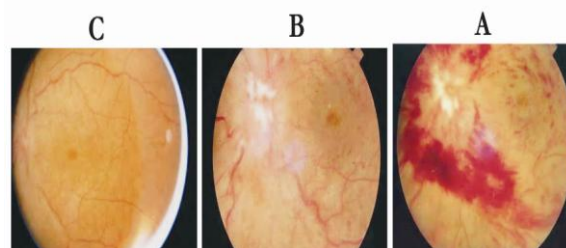


Figure 1: Fundus photograph in patient 4 before (A) and after treatment (B): at three months follow up visit, (C): one month after niacin cessation, at 4 months follow up visit), showed resolution of macular and disc edema and reduction of areas of hemorrhages Macular hole appeared at three months after the beginning of niacin (photograph: B and C)

Fourteen patients had ischemic CRVO, five had non-ischemic CRVO, and one patient presented with a macular BRVO. There was a serum lipid abnormality (TG>200 mg/d, LDL>160 mg/d, or

HDL <40 mg/dl) in seven patients. Demographic data, systemic risk factors and lipid profile abnormalities are listed in Table 1.

Table1: Demographic data, systemic risk factors and lipid profile abnormality

Patient	Age	Gender	Risk factor	Lipid profile abnormality
1	60	Male	Anti-phospholipid antibody syndrome	High TG, High LDL, Low HDL
2	35	Male	-	High TG, High LDL, Low HDL
3	42	Female	-	High TG, High LDL, Low HDL
4	54	Female	Hypertension	Low HDL
5	55	Male	-	High LDL
6	63	Male	Hypertension	-
7	67	Male	-	High TG, Low HDL
8	66	Male	-	High TG, High LDL, Low HDL
9	64	Male	Hypertension	-
10	55	Male	-	-
11	82	Female	-	-
12	60	Female	-	-
13	29	Male	Diabetes mellitus	-
14	54	Male	-	Not available
15	66	Male	Hypertension	-
16	60	Female	-	Not available
17	60	Female	-	-
18	68	Female	Hypertension	-
19	63	Female	-	Not available
20	53	Male	-	-
21	73	Female	-	-

TG more than 200mg/d, LDL more than 160 and HDL less than 40mg/dl were considered as abnormal.

One patient experienced generalized urticaria due to nicotinic acid and was excluded from the study.

We discontinued treatment with nicotinic acid due to uncontrollable blood glucose levels two months after treatment was commenced in the patient with diabetes. Four patients did not follow the treatment protocol for three months and their data were excluded from the study. Therefore, the results of treatment in 16 eyes of 15 patients who completed the therapeutic course of nicotinic acid and were followed for at least three months are reported.

These patients had a mean age of 59.56 ± 11.12 years (range: 35 to 82 years). The average length of follow-up was 8.6 ± 2.7 months (range: 3 to 12 months). The average duration of symptoms at the time of treatment was 59.69 ± 71.60 days (range 10-240 days).

The mean BSCVA was 1.56 ± 0.66 before treatment, 1.38 ± 0.72 (p>0.05) at one month and 0.88 ± 0.69 (p<0.01) at three months. The last BSCVA of all 16 eyes averaged 0.97 ± 0.73 (p<0.01). In the final follow-up visit, eight eyes (50%) had maintained their pre-treatment vision and others showed a significant increase in VA. Among eight eyes with ischemic CRVO; four eyes have more than 3 lines increase in VA and other did not show change in VA.

Patient with bilateral multiple BRVOs had significant improvement of VA in left eye and no change of VA in right eye. Only 2 eyes (40%) with non-ischemic CRVO showed 3 lines increase in CRVO and other maintained their VA. The percentage of patients who had a best-corrected vision worse than 20/200 decreased from 68.7% (11 eyes) at first presentation to 31.2% in the last follow-up visit. The pre-and post-treatment ocular data are shown in Table 2.

Table 2: Summary of pre- and post-treatment for patients treating with nicotinic acid

Patient	ONSET (days)	BCVA0	RAPD	TYPE*	BCVA3	Follow up (months)	Last BCVA
1(eye1)	180	2.0	2	Mu-BRVO	0.7	12.00	2.0
1(eye2)	180	2.0	-	Mu-BRVO	0.2	12.00	0.7
2	30	2.0	3	I-CRVO	0.2	6.00	0.2
3	15	2.0	3	I-CRVO	0.9	8.00	0.7
4	45	2.0	0	M-BRVO	0.7	11.00	0.5
5	30	0.7	1	N-CRVO	0.7	6.00	0.7
6	30	0.9	3	I-CRVO		Niacin intolerance	
7	20	2.0	3	I-CRVO	0.7	11.00	0.7
8	240	0.7	1	N-CRVO	0.3	10.00	0.3
9	10	2.0	3	I-CRVO	0.40	11.00	0.7
10	45	0.7	1	N-CRVO	0.5	9.00	0.1
11	30	0.7	1	N-CRVO	0.7	9.00	0.7
12	40	0.3	1	N-CRVO	0.2	7.00	0.3
13	10	2.0	3	I-CRVO		Niacin intolerance	
14	35	2.0	3	I-CRVO	2.0	6.00	2.0
15	30	2.0	3	I-CRVO	2.0	6.00	2.0
16	21	0.6	3	I-CRVO		Miss to follow up	
17	11	2.0	3	I-CRVO	2.0	3.00	2.0
18	40	2.0	3	I-CRVO		Miss to follow up	
19	30	2.0	3	I-CRVO		Miss to follow up	
20	21	2.0	3	I-CRVO		Miss to follow up	
21	14	2.0	3	I-CRVO	2.0	11.00	2.0

I-CRVO = Ischemic CRVO, N-CRVO=Non-ischemic CRVO, M-BRVO=Macular BRVO, Mu-BRVO =Multipl BRVO, BCVA0= BCVA before treatment, BCVA3=BCVA at 3 months follow up visit, Last BCVA=BCVA at more than 3 months follow up visit (for patients with complete therapeutic course of niacin), HM = hand motion.

*According to visual acuity, RAPD, and fundus appearance.

Perimetry was performed in ten patients before treatment and at the three month follow-up visit. An improvement in visual field perception was seen in eight of these patients. In other patients, the perimetry results were not reliable because of co-existing poor VA or poor cooperation with the test. We considered the mean deviation (MD) to be an indicator of general visual field sensitivity. The MD index improved from -29 ± 9 before treatment, to -24 ± 7 ($p < 0.01$) at three months, and to -28 ± 9 ($p < 0.05$) in the last follow-up visit.

Patient # 8, had persistent macular edema eight months after RON. His lipid profile showed the need for treatment with a lipid-lowering agent. Therefore, we considered him as eligible to participate in this study in order to evaluate the effect of nicotinic acid on macular edema. Three months after beginning treatment, his vision had improved by four lines, the macular edema was reduced, and the focal field defect in perimetry had disappeared.

Resolution of hemorrhages, cotton wool spots, macular edema, disc edema, venous tortuosity, and venous dilatation were detected in all eyes by approximately three months after starting treatment (Figure 1 and 2).

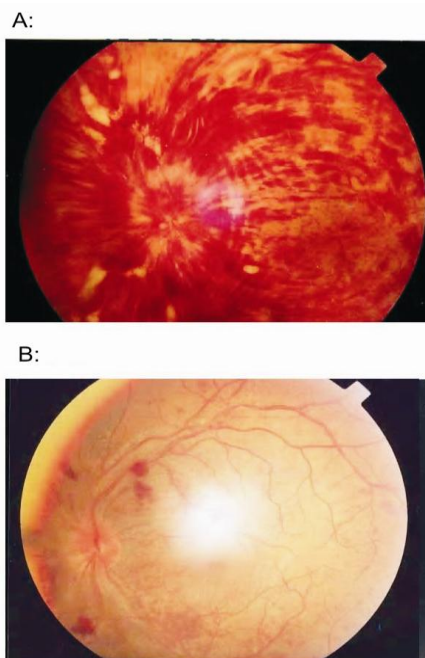


Figure 2: Lipid profile changes: TG, LDL reduced, and HDL increased 3 months after treatment. The changes were statistically significant. At the last follow up visit (by average 4.2 months after niacin discontinuation), lipid profile did not show statistically significant difference from pre-treatment values

Ocular complications occurred in four eyes (50%) in the ischemic group. The major ocular complication was neovascularization. One eye developed retinal neovascularization, three months after the discontinuation of nicotinic acid. One patient presented with a vitreous hemorrhage, seven months after cessation of the treatment with nicotinic acid and one patient during treatment. We also detected neovascularization of the iris in Patient # 9, three months after treatment. A macular hole developed in one eye and was the only non-neovascular complication in this series.

Systemic results

The mean pre-treatment serum TG, LDL, HDL levels were 188 ± 56 , 148 ± 22 , and 40 ± 9 mg/dl, respectively. Three months after treatment, the mean TG and LDL levels decreased to 151 ± 35 mg/dl ($p < 0.01$) and 139 ± 19 mg/dl ($p < 0.05$), and the mean HDL increased to 52 ± 9 mg/dl ($p < 0.05$). (Figure 3) In the last follow-up visit, which occurred at an average of 4.2 months after the discontinuation of nicotinic acid, the lipid profile did not show a statistically significant difference from pre-treatment values ($p > 0.05$).

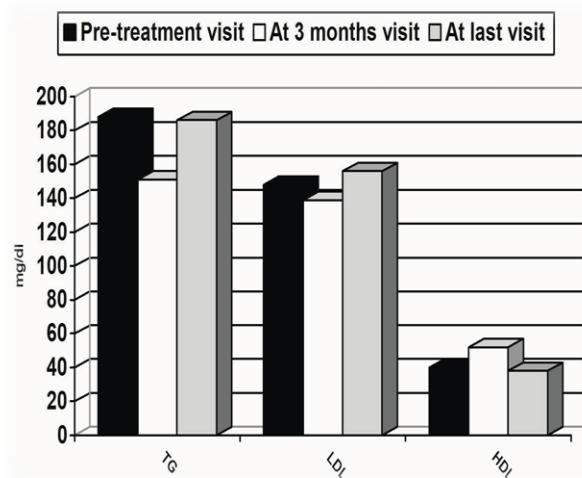


Figure 3: Fundus photograph in patient 3 before treatment (A) and at three months follow up visit (B). Foveal thickness was decreased 3 months after starting the treatment

The mean fasting blood glucose (FBS) level increased from 93 mg/dl to 102 mg/dl, three months after treatment ($p < 0.05$). As mentioned earlier, there was one diabetic patient who developed uncontrollable hyperglycemia, two months after starting treatment; therefore, in their case the drug was discontinued. After cessation of nicotinic acid, their FBS returned to pre-treatment values.

The systemic side effects of nicotinic acid included skin flushing (which decreased after the first month in all patients), uncontrollable high glucose levels in the diabetic case, and urticaria in a single patient.

Generally, the systemic side effects were mild and well tolerated.

Discussion

To the best of our knowledge this is the first report in the ophthalmic literature, based on a Pubmed search, on the treatment of RVO with nicotinic acid.

The prognosis of CRVO in eyes with a baseline VA of less than 20/200 is poor (14). Treatment with pan-retinal laser photocoagulation and macular grid pattern laser, does not improve the final VA (1-2).

There is 80% chance that eyes with initial visual acuity of worse than 20/200, will have final visual acuity less than 20/200 without treatment (14), but this chance was only 31% in the current series which seems significantly better than natural history of the disease.

One can argue that the classification of patients into ischemic and non-ischemic groups, according to the results of the BSCVA, RAPD and appearance of the fundus may not be correct. Hayreh et al (15) demonstrated that the information derived from fluorescein angiography during the early phases of CRVO may be deceptive, and a combination of four tests (VA, visual fields, relative afferent pupillary defect, and electroretinography) may contribute to classifying CRVO in a more reliable manner. The limitation of this study was that we used only VA and RAPD in this regard.

One major concern is whether the beneficial effects of the drug persist after its discontinuation.

Although our data showed that the effect of nicotinic acid persisted after the discontinuation of the drug, a longer follow-up may show that this was a temporary effect.

Major ocular complications reported in this study occurred in the ischemic group. Neovascular complications developed in 50% of the ischemic group, which is similar with the rate of 60% reported in the CRVO Study Group (14).

Patients with CRVO have a higher risk of cardiovascular events (16). Therefore, it is very important to diagnose and treat cardiovascular risk factors in these patients. There was a high rate of serum lipid abnormalities in the current series, and nicotinic acid is useful in the treatment of hyperlipidemia. Several clinical trials show that nicotinic acid prevents or treats cardiovascular disease and reduces total mortality rate (17).

Therefore, nicotinic acid may help to improve the serum lipid profile of patients and reduce the risk of adverse cardiovascular events in addition to its effect on CRVO.

Gass (18) first described cystoid macular edema (CME) induced by nicotinic acid, which occurs usually in patients receiving high doses (more than 1.5 g/day) for a period of more than six weeks.

Although the exact pathological mechanisms of CME remain unclear, the prostaglandin-induced toxicity of Muller cells (19) or the subtle breakdown of the blood-ocular barrier have been suggest (20).

We were unable to document nicotinic acid-induced CME in the current series because we did not perform fluorescein angiography.

In this study, aspirin was used to reduce the cutaneous reactions that resulted as a consequence of nicotinic acid administration in an attempt to increase patient tolerance. The vasodilatory effect of nicotinic acid seems to be mediated by the release of endogenous prostaglandins, especially PGD₂ (12-13), and is not dependent on its lipid-lowering effect (21). The recommended dose of aspirin is 325 mg/day (22), but we used a lower dose of aspirin (100 mg/day) for a brief time. This was in order to limit the possibility of counteracting nicotinic acid-induced retinal vasodilation due to the inhibiting effect of aspirin on prostaglandins. Despite this low dose of aspirin, the systemic side effects encountered in this study, were mild and well tolerated. The role of systemic anticoagulation in the prevention or treatment of CRVO is unclear.

Koizumia et al (23) demonstrated that the use of aspirin is an independent risk factor for CRVO.

However, aspirin may act as confounding factor in this study.

Our study has the following limitations:

1. It is not a blind study, and significant bias may be present in data collection.
2. Method of treatment may need to be modified.

We are also not certain about the optimum dose of niacin and aspirin and about persistence of drug effects. Longer follow up may show reduced or even, rebound effect.

3. Improved visual acuity on follow-up, does not necessarily reflect a genuine visual improvement.

Visual acuity measured at the first visit can be unreliable and deceptively poor, because the patient, having suddenly lost vision, may be emotionally upset and poorly cooperative. In due course, the patient learns by experience to read the test chart better, looking around and fixating eccentrically.

4. A major limitation of our study is the lack of a well-matched control group to compare for the effect of natural course of the disease.

References

- 1- The Central Vein Occlusion Study Group N report. A randomized clinical trial of early panretinal photocoagulation for ischemic central vein occlusion. *Ophthalmology*. 1995; 102(10):1434-44.
- 2- The Central Vein Occlusion Study Group M report. Evaluation of grid pattern photocoagulation for macular edema in central vein occlusion. *Ophthalmology*. 1995; 102(10): 1425-33.
- 3- Branch Vein Occlusion Study Group: Argon laser photocoagulation for macular edema in branch vein occlusion. *Am J Ophthalmol*. 1984; 98(3):271-82.
- 4- Branch Vein Occlusion Study Group: Argon laser scatter photocoagulation for prevention of neovascularization and vitreous hemorrhage in branch vein occlusion: a randomized clinical trial. *Arch Ophthalmol*. 1986; 104(1):34-41.
- 5- Weiss JN, Bynoe LA. Injection of tissue plasminogen activator into a branch retinal vein in eyes with central retinal vein occlusion. *Ophthalmology*. 2001; 108(12):2249-57.
- 6- Vijayasekaran S, Yu DY, McAllister I, Barry C, Constable I. Optimal conditions required for the creation of an iatrogenic chorioretinal venous anastomosis in the dog using argon green laser photocoagulation. *Curr Eye Res*. 1995; 14(1):63-70.
- 7- McAllister IL, Constable IJ. Laser-induced chorioretinal venous anastomosis for treatment of nonischemic central retinal vein occlusion. *Arch Ophthalmol*. 1995; 113(4):456-62.
- 8- Lit ES, Tsilimbaris M, Gotzaridis E, D'Amico DJ. Lamina puncture: Pars plana optic disc surgery for central retinal vein occlusion. *Arch Ophthalmol*. 2002; 120(4):495-9.
- 9- Opremcak EM, Bruce RA, Lomeo MD, Ridenour CD, Letson AD, Rehmar AJ, et al. Radial optic neurotomy for central retinal vein occlusion: A retrospective pilot study of 11 consecutive cases. *Retina*. 2001; 21(5):408-15.
- 10- Horio N, Horiguchi M. Effect of arteriovenous sheathotomy on retinal blood flow and macular edema in patients with branch retinal vein occlusion. *Am J Ophthalmol*. 2005; 139(4):739-40.
- 11- Carlson LA. Nicotinic acid: the broad-spectrum lipid drug. A 50th anniversary review. *J Intern Med*. 2005; 258(2):94-114.
- 12- Eklund B, Kaijser L, Nowak J, Wennmalm A. Prostaglandins contribute to the vasodilation induced by nicotinic acid. *Prostaglandins*. 1979; 17(6):821-30.
- 13- Morrow JD, Parsons WG 3rd, Roberts LJ 2nd. Release of markedly increased quantities of prostaglandin D2 in vivo in humans following the administration of nicotinic acid. *Prostaglandins*. 1989; 38(2):263-74.
- 14- The Central Vein Occlusion Study Group. Natural history and clinical management of central retinal vein occlusion. *Arch Ophthalmol*. 1997; 115(4): 486-491.
- 15- Hayreh SS, Klugman MR, Beri M, Kimura AE, Podhajsky P. Differentiation of ischemic from non-ischemic central retinal vein occlusion during the early acute phase. *Graefes Arch Clin Exp Ophthalmol*. 1990; 228(3):201-17.
- 16- Prisco D, Marcucci R, Bertini L, Gori AM. Cardiovascular and thrombophilic risk factors for central retinal vein occlusion. *Eur J Intern Med*. 2002; 13(3):163-169.

As yet, there are no reported randomized controlled trials with a longer follow-up period than our study. Such a study would help to determine whether nicotinic acid actually improves the overall visual outcome in CRVO and BRVO.

Acknowledgement

We would like to thank all the faculty members of Khatam-al-Anbia Hospital at Mashhad University of Medical Sciences. We are also grateful to the numbers of eye research center of Khatam-al-Anbia Hospital for supporting this project.

- 17- Guyton JR. Effect of niacin on atherosclerotic cardiovascular disease. *Am J Cardiol.* 1998 17; 82(12A):18U-23U; discussion 39U-41U.
- 18- Gass JD. Nicotinic acid maculopathy. *Am J Ophthalmol.* 1973; 76(4):500-10.
- 19- Jampol LM. Niacin maculopathy. *Ophthalmology.* 1988; 95(12):1704-5.
- 20- Spirn MJ, Warren FA, Guyer DR, Klancnik JM, Spaide RF. Optical coherence tomography findings in nicotinic acid maculopathy. *Am J Ophthalmol.* 2003; 135(6):913-4.
- 21- Whelan AM, Price SO, Fowler SF, Hainer BL. The effect of aspirin on niacin-induced cutaneous reactions. *J Fam Pract.* 1992; 34(2):165-8.
- 22- Kaijser L, Eklund B, Olsson AG, Carlson LA. Dissociation of the effects of nicotinic acid on vasodilatation and lipolysis by a prostaglandin synthesis inhibitor, indomethacin, in man. *Med Biol.* 1979; 57(2):114-7.
- 23- Koizumi H, Ferrara DC, Bruè C, Spaide RF. Central retinal vein occlusion case-control study. *Am J Ophthalmol.* 2007; 144 (6):858-863.